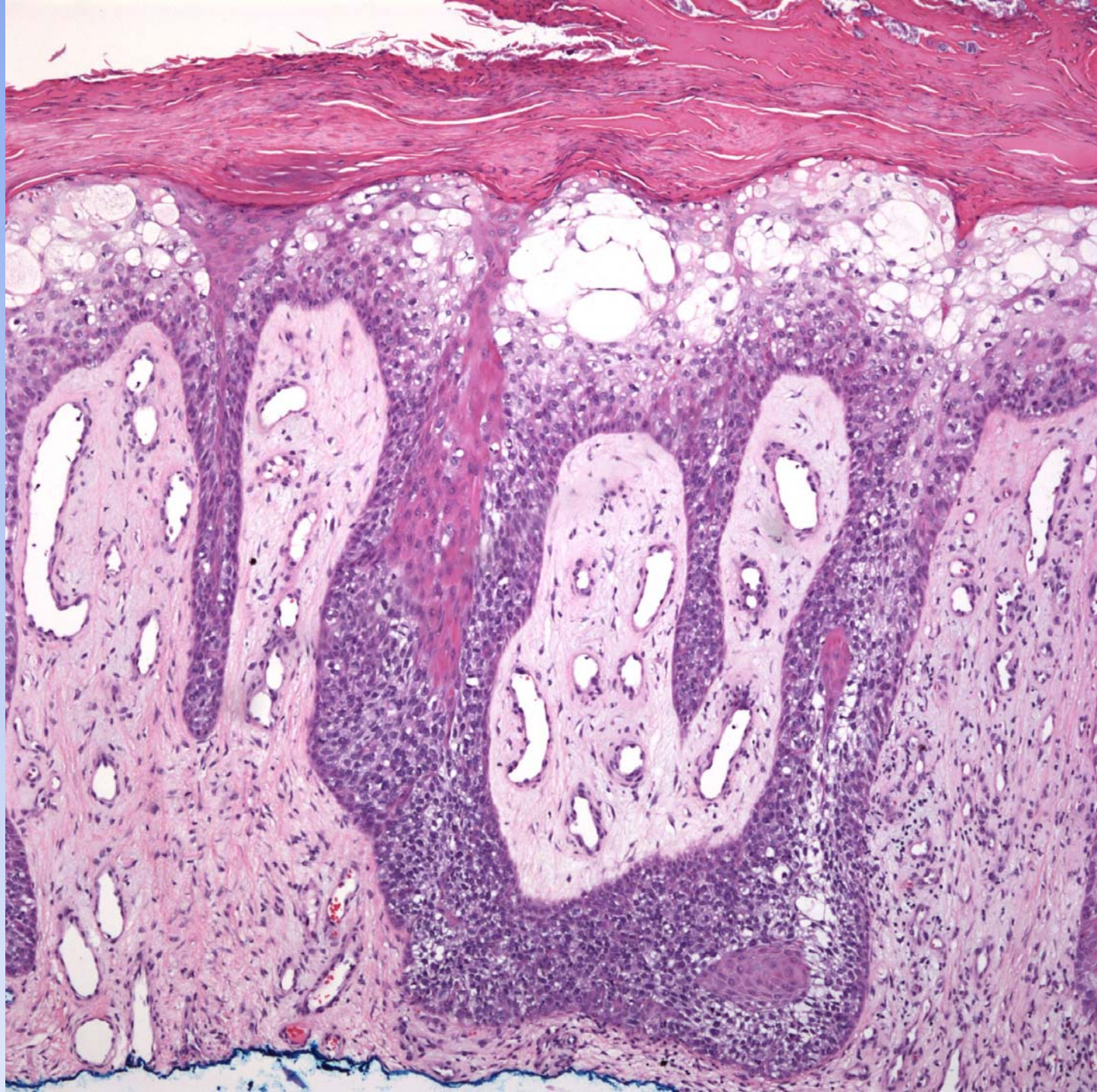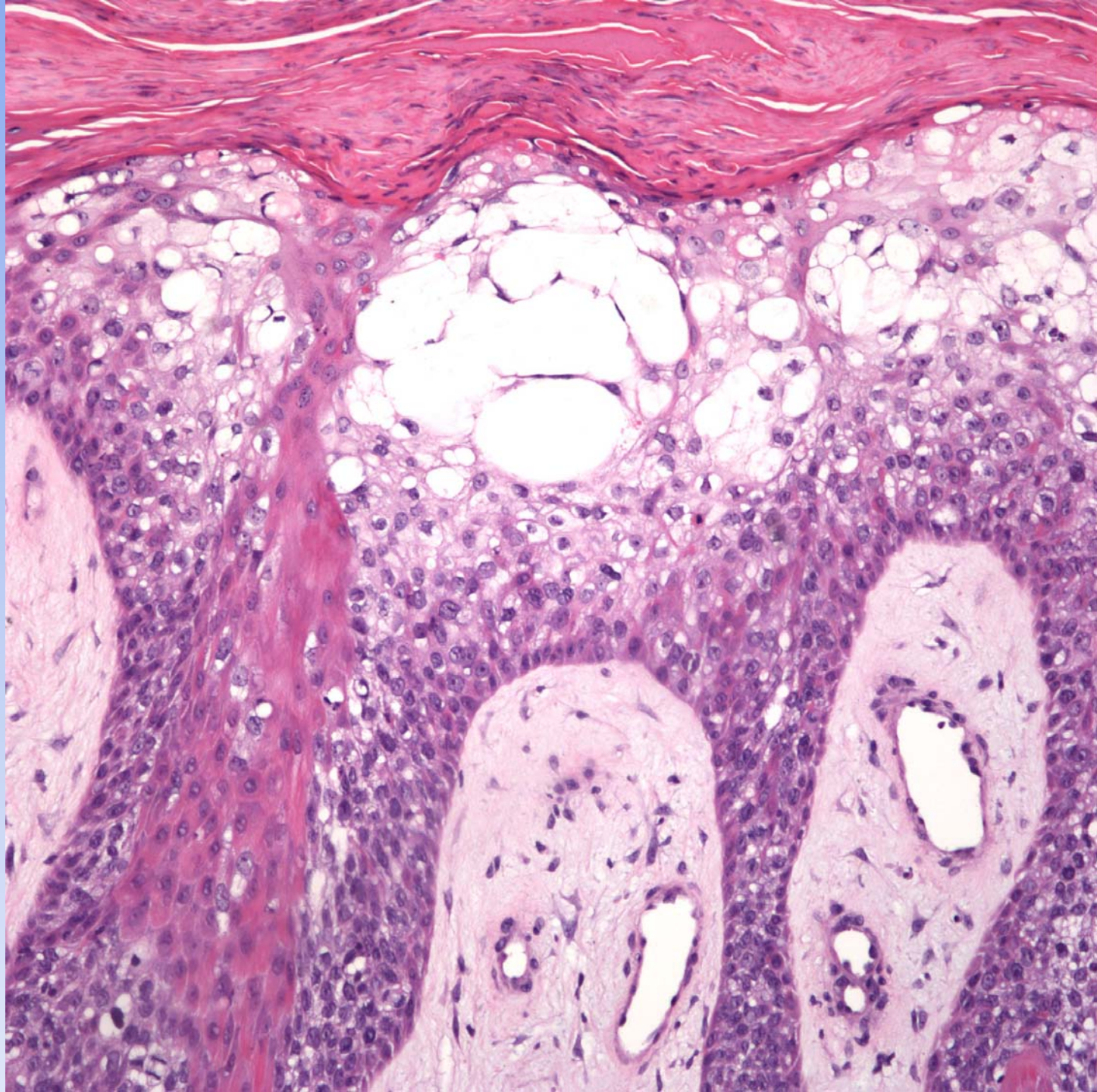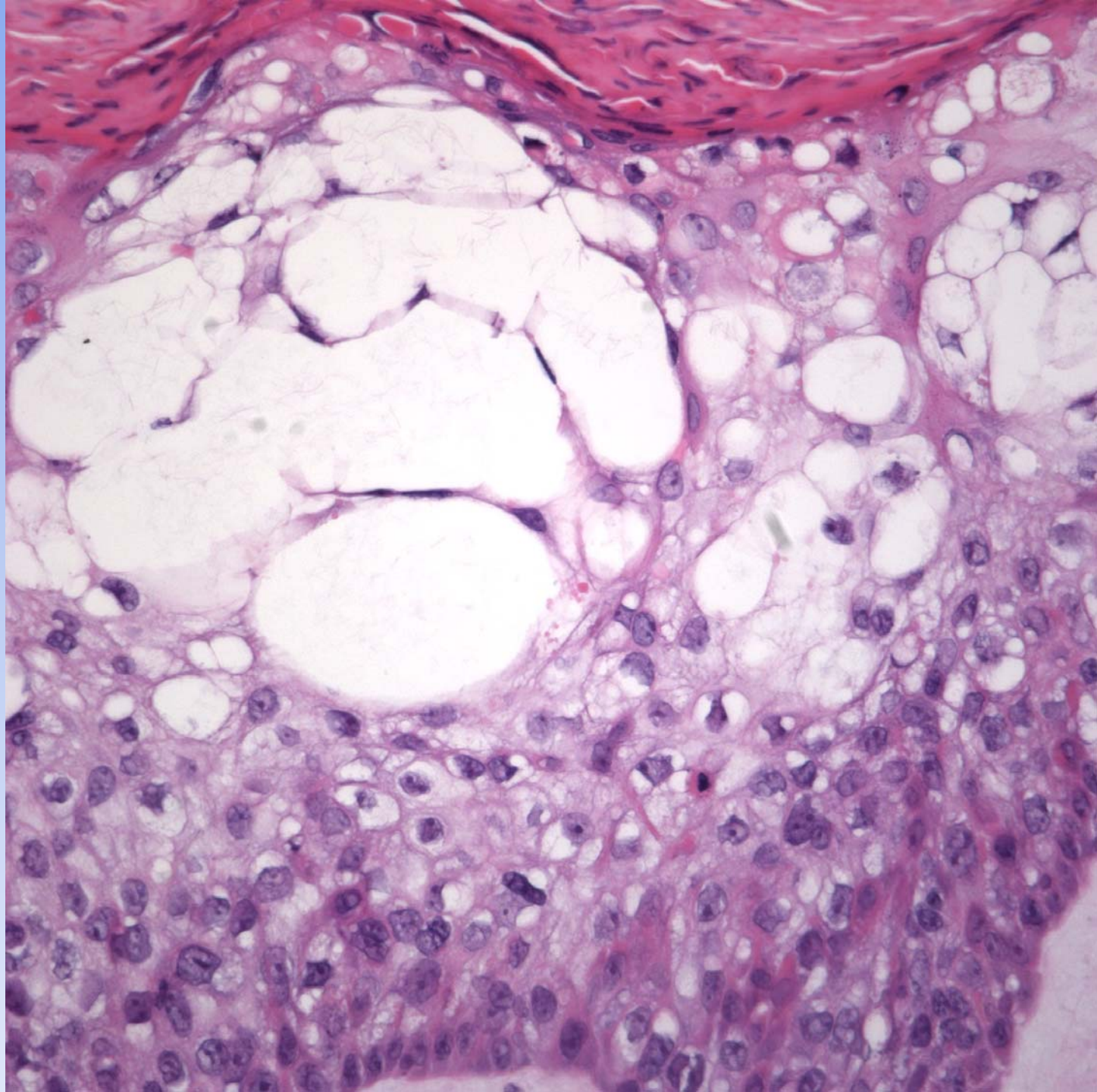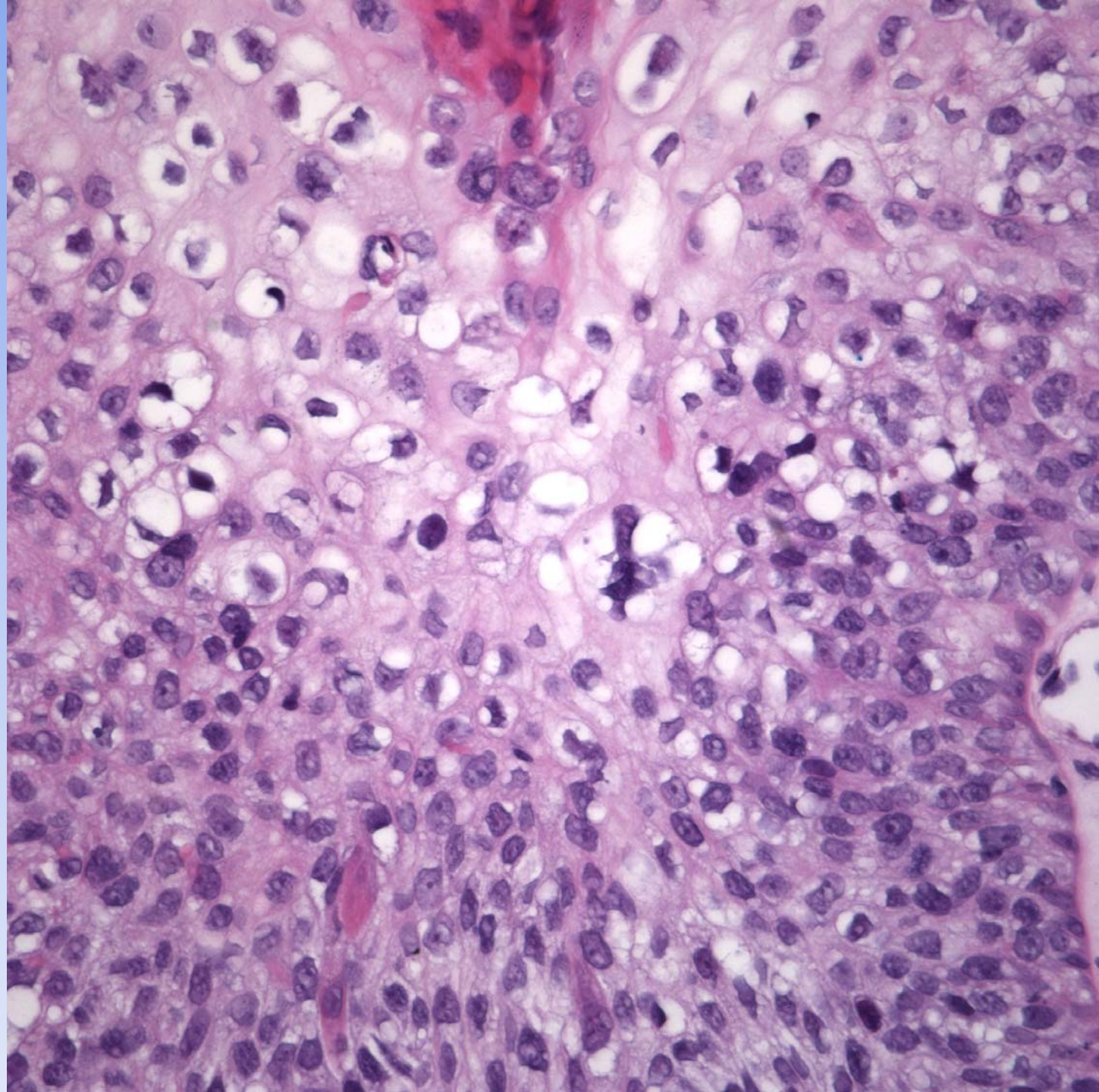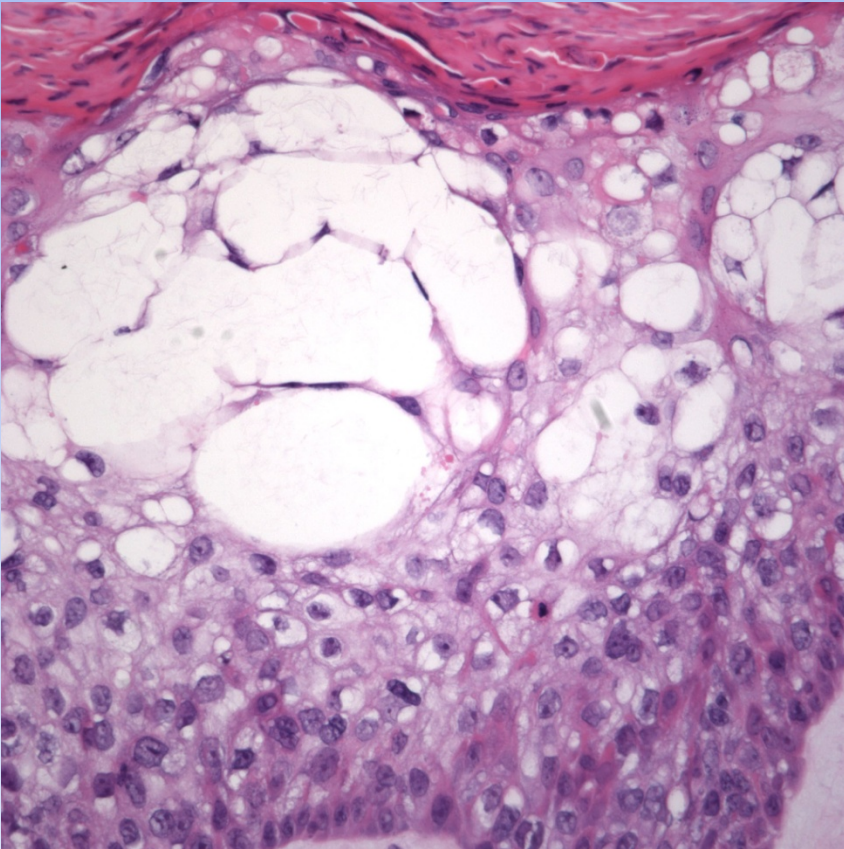


# Bowen's Disease-Clear Cell Type

# Pearls



- Full thickness replacement of epidermis with atypical keratinocytes
- Loss of polarity
- Dyskeratotic keratinocytes
- Atypical mitotic figures
- No follicular sparing
- Clear cell change may represent glycogen or degenerative changes